Journal of ISAKOS: Joint Disorders & Orthopaedic Sports Medicine Publish Ahead of Print, published on March 22, 2016 as doi:10.1136/jisakos-2015-000033

Diagnosis and treatment of anterior knee pain

Vicente Sanchis-Alfonso,[1] Jenny McConnell,[2] Joan Carles Monllau,[3] John P Fulkerson[4]

[1]Department of Orthopaedic Surgery, Hospital Arnau de Vilanova and Hospital 9 de Octubre, Valencia, Spain
[2]McConnell Physiotherapy Group, Centre for Sports Medicine Research and Education, University of Melbourne, Melbourne, Victoria, Australia
[3]Department of Orthopaedic Surgery and Traumatology, Hospital del Mar, Universitat Autònoma de Barcelona, Barcelona, Spain
[4]Department of Orthopaedic Surgery, Orthopedic Associates of Hartford; University of Connecticut Medical School, Farmington, Connecticut, USA

Correspondence to
Dr Vicente Sanchis-Alfonso, Department of Orthopaedic Surgery, Hospital Arnau de Vilanova and Hospital 9 de Octubre, Avd Cardenal Benlloch 36, 23, Valencia 46021, Spain; vicente.sanchis.alfonso@gmail.com

Received 30 December 2015
Revised 23 February 2016
Accepted 2 March 2016

ABSTRACT

Anterior knee pain (AKP) is one of the most frequent reasons for adolescents and young adults to seek consultation for knee conditions. Owing to the complex multifactorial aetiology of AKP, with local, proximal and distal factors potentially involved, its treatment is particularly difficult and challenging for the practitioner. A careful history and physical examination are crucial for an accurate diagnosis and therefore a correct treatment. The entire lower extremity should be examined, with findings complemented by imaging studies to arrive at a diagnosis. Arriving at a precise diagnosis is the cornerstone of developing an appropriate treatment. Given that the aetiology of AKP is multifactorial, individualised treatment must be tailored to the patient. Early intervention is very important to maximise the chance of a good prognosis. Non-surgical management is effective in the majority of patients. Surgery is indicated solely in cases with pain that is refractory to non-operative treatment and well-defined structural abnormalities that are deemed to be the cause of the AKP can be targeted for repair or correction.

BACKGROUND, PREVALENCE, AND SOCIETAL IMPACT

Anterior knee pain (AKP) is one of the most frequent reasons for consultation in the context of knee conditions in adolescent and young adult patients, accounting for up to 74% of knee pain experienced by adolescents participating in sports.[1] Nejati *et al*[2] found the prevalence rate of AKP to be 16.7% in a study performed in a sports medicine clinic. This rate was similar to that shown by Boling *et al*[3] in a study that involved participants from the US Naval Academy. Boling *et al*[3] found a prevalence of 15% in females and 12% in males. They also observed that the annual incidence of AKP was 33 of 1000 people in female patients, but only 15 of 1000 people in male patients. Gender is a significant predictor for the development of AKP, with females having an incidence that is 2.23 times higher than that of males.[3] However, the incidence of AKP in the general population is unknown.

Treating patients with AKP is often frustrating, both for the orthopaedic surgeon and for the physiotherapist. Collins *et al*[4] have shown 40% of unfavourable recovery at 12 months after the initial diagnosis. Moreover, between 70% and 90% of individuals with AKP have recurrent or chronic pain.[5] Chronic pain is a multidimensional experience that requires consideration of sensory features as well as affective and cognitive features.[6] That is to say, chronic pain affects a patient psychologically. AKP provokes both psychological limitations and disability, which may arise more from the psychological affectation than from the pain itself.[7] The WHO defines disability as 'a limitation of function that compromises an individual's ability to perform an activity within the range considered normal'. Such limitations may impose a change in a patient's lifestyle. Since AKP frequently occurs in young working adults, it has an important societal impact due to work absences and lost productivity as well as the economic expense involving in treating these patients.[8] AKP is frequently met with a lack of understanding within a patient's circle of acquaintance, which worsens the psychological affectation. Moreover, patients with AKP may also have an increased risk of developing patellofemoral osteoarthritis (PFOA).[9] In summary, AKP has a negative impact on patients' quality of life. As an indicator of the importance of this clinical entity, the Chartered Society of Physiotherapy in the UK has ranked AKP as the third most important topic out of 185 listed in their Musculoskeletal Research Priority Project.[10]

The goal of this paper is to analyse in detail how to better reach a diagnosis and therefore identify the most suitable treatment in individual cases. We emphasise that the aetiology of AKP is multifactorial, involving local, proximal and distal factors, which leads to there being many subsets of patients with AKP. Hence, there is no single treatment. Treatment has to be tailored to the individual patient. In box 1, we outline 10 articles that the authors of this paper found to be key in the development of evaluation and treatment of AKP.

DIAGNOSIS

The patient's clinical history and physical examination are of paramount importance in diagnosing the cause of AKP. The physical examination is complemented by imaging studies, and the combination should yield a precise diagnosis that will be the cornerstone in developing an appropriate therapeutic programme. It must be emphasised that the cause of AKP should be a diagnosis of exclusion.

History

First, a complete history of the patient's symptoms is required to diagnose. We must listen to the patient carefully. In any pathological entity, listening to the patient is essential, but in the one we deal with in this paper, it is even more important.

The main symptom experienced by a patient with AKP is retropatellar or peripatellar pain. The location of the pain is crucial for making a diagnosis. However, it is often difficult for a patient to isolate the focus of pain. In response to a query about the pain's location, he or she may simply put a hand over the anterior aspect of the knee. The pain may even be popliteal. Pain diagrams, on which patients indicate the site of pain on drawings of the knee, could be helpful. It is also important to determine whether the pain appears, or is aggravated by

To cite: Sanchis-Alfonso V, McConnell J, Monllau JC, *et al*. *JISAKOS* Published Online First: [*please include* Day Month Year] doi:10.1136/jisakos-2015-000033

activities that load the patellofemoral joint (PFJ), such as climbing and descending the stairs, squatting, using a car clutch (if the left knee is in pain), wearing high-heeled shoes, and sitting with prolonged knee flexion (-movie sign-), and whether extending the knee improves the pain.

Aside from pain, other symptoms are a giving-way sensation —walking straight on, especially when using the stairs or ramps, and crepitus. The giving-way episodes are due to a sudden reflex inhibition and/or atrophy of the quadriceps. It is important to establish if patellar instability is associated with the pain since both the treatment and the prognosis are very different in the patient with AKP secondary to patellar instability compared with the patient with AKP without patellar instability. Crepitus is common, although it is insignificant in most cases. For example, Abernethy *et al*[21] found asymptomatic crepitus in 62% of first-year medical students.

AKP onset is generally insidious and without trauma, which reflects an overuse condition or an underlying malalignment. Overuse can be brought on by a new activity or an increase in frequency or intensity of a customary activity. History should be geared towards determining which supraphysiological loading activity is of importance in the origin of AKP. The identification and careful management of the activities associated with the onset and endurance of AKP are key elements for successful treatment.[18] Symptoms in both knees are common and may move from one knee to the other over time.

AKP is often described as dull with intermittent episodes of sharp acute pain. In obtaining the history, it is important to quantify the pain. Pain is sometimes disproportionate due to existing hyperalgesia (heightened reaction to stimuli, ie, normally painful) or allodynia (pain due to stimuli that do not usually bring on pain).[22] These patients belong to the AKP subset of neuropathic pain. Finally, in cases preceded by realignment surgery in which pain and disability are much worse than the preoperative symptoms that prompted surgery, there should be suspicion of an iatrogenic medial patellar instability (IMPI).[23]

In addition to pain, which is the fundamental symptom, these patients experience disability to a greater or lesser degree. Therefore, it is also important to quantify the disability.

Patients with AKP very often experience anxiety, depression, kinesiophobia (the fear that a manoeuvre will cause more injury or a reinjury and pain) and catastrophising (the belief that pain will worsen and cannot be relieved).[7] These psychological factors play an important role as pain modulators. Even if the structural findings are clear, psychological factors influence and modify pain sensation as well as subsequent impairment and can serve as barriers to recovery.[20] Therefore, it is essential to recognise and quantify the existence of these psychological issues to have a holistic view of a particular patient and plan the best treatment (box 2).

Physical examination

The first objective of physical examination is to pinpoint the painful area, and to replicate the symptoms. The location of the

Box 1 Key articles (historic evolution), according to the authors, on anterior knee pain (AKP)

- Merchant *et al*[11] in 1974 described in depth the roentgenographic analysis of patellofemoral congruence.
- Fulkerson[12] described in 1983 the anteromedialisation of the tibial tuberosity.
- In 1985, Fulkerson *et al*[13] was the first to describe nerve damage in the lateral retinaculum of patients with intractable patellofemoral pain requiring lateral retinacular release or realignment of the patellofemoral joint. He stated that it is likely that the lateral retinaculum itself is painful in many patients with patellofemoral malalignment.
- Hughston and Deese[14] described, for the first time in 1988, medial patellar instability as a complication of lateral retinacular release that provokes incapacitating AKP.
- McConnell[15] was the first, in 1996, to propose the use of tape to exert a force on the patella to improve alignment and tracking, this way AKP is diminished.
- Sanchis-Alfonso *et al*,[16] in 1998, performed a quantitative analysis of nerve changes in the lateral retinaculum in patients with AKP.
- Powers,[17] in 2003, introduced one of the most important concepts of the past 13 years in AKP aetiology: the proximal control. This new philosophy links abnormal femur rotation with AKP. The rotation of the femur underneath the patella in the transverse plane leads to abnormal patellar tracking and therefore patellofemoral imbalance and finally pain. This means that the primary problem is not in the patella but in the femur.
- Dye[18] popularised in 2005 the tissue homeostasis perspective to evaluate and treat patients with AKP. According to Dye, the loss of both osseous and soft tissue homeostasis is more important in the genesis of AKP than structural characteristics.
- Näslund *et al*,[19] in 2007, demonstrated the importance of ischaemia in the genesis of pain in a subset of patients with AKP
- Domenech and Sanchis-Alfonso[7 20] performed in 2013 and 2014 the most detailed analysis of psychological factors acting as pain modulators in AKP.

Box 2 Outcome measures

- Using tools such as the Visual Analogue Scale (VAS) of pain is important in order to quantify the pain at baseline and to demonstrate and monitor improvement with the treatment. The 10 cm VAS is a valid and responsive outcome measure for anterior knee pain, with a minimum clinically important difference of 2 cm.[24]
- If the presence of neuropathic pain is suspected, validated self-administered scales that are specific for neuropathic pain, such as the Leeds Assessment of Neuropathic Symptoms and Signs (LANSS) Pain Scale, should be used.[25]
- Algometry may help clinicians in recognising patients with complex regional pain syndrome (CRPS). If surgeons are aware of the extent of the CRPS preoperatively, they would be very cautious to not operate as the symptoms will only worsen.
- The disability may be quantified by using specific validated functional self-administered scales such as the Kujala test[26] and the Tegner activity scale.[27] It is also necessary to know a patient's activity level prior to the treatment and his/her objectives in order to review realistic goals of the treatment.
- We should routinely incorporate validated self-administered screening tests for anxiety and depression—Hospital Anxiety and Depression Scale (HADS),[28] catastrophising—Pain Catastrophizing Scale (PCS),[29] and kinesiophobia—Tampa Scale for Kinesiophobia (TSK)[30] in a patient's history.

pain is crucial because it is able to indicate the injured structure, which is really helpful in diagnosing and planning treatment. Tenderness over the lateral retinaculum is a frequent finding. Therefore, we must evaluate lateral retinaculum tightness using the patellar glide test.[31] In order to exclude the possibility that AKP originates in the patellofemoral articular surfaces, the axial patellar compression test is used.[31] Moreover, the sustained knee flexion test allows one to rule out pain brought on by an increase in intraosseous patellar pressure.[32] Palpation of the inferior pole of the patella must be performed in all cases because pain is very frequently located in that area.[31] Moreover, Hoffa's fat pad should not be overlooked as a cause of pain; it should always be examined while performing Hoffa's test because it can be a source of disabling pain (figure 1).[33] Existing scars should be palpated and Tinel's sign carried out to detect neuromas. Improvement in the patient's pain after selective injection with local anaesthetics or with unloading functional taping leads us to think that specific knee soft tissue may be the origin of pain. When a neuropathic origin of pain is suspected, pressure algometry, which provides a measurement of pressure pain threshold by applying progressive pressure to a given body point using an algometer, is helpful. Female adolescents with AKP have been demonstrated to have a lower pressure pain threshold in comparison with a control group.[22]

Most patients with AKP will develop a quadriceps avoidance gait pattern to decrease the PFJ reaction force and thereby the pain.[31] Notably, a knee extension strength deficit appears to be a predictor of AKP.[34] Hence, it is mandatory to evaluate quadriceps atrophy and isometric strength of the quadriceps, which can be done with a manual dynamometer.

Moreover, it is necessary to evaluate the flexibility in the quadriceps, hamstring, gastrocnemius muscles, the iliotibial band (ITB) and anterior hip structures (figure 2), given that AKP is frequently associated with a reduced flexibility of these structures.[31]

Baker *et al*[35] showed abnormal knee joint proprioception in those with AKP. Although they could not determine if the abnormality preceded AKP or was secondary to it, their results support the inclusion of specific proprioceptive training in treatment. The active or passive joint position reproduction can be used to evaluate proprioception.

Normally, when a patient with AKP is seen in a clinic, the focus is on the knee and only that structure is studied. This focus is a mistake, because other important aetiological factors distant from the knee can be responsible for the pain.[36] Strong evidence currently exists that patients with AKP have deficits in hip abduction, hip extension and external rotation strength.[37] Therefore, it is mandatory in the clinical examination to evaluate hip abduction strength, hip extension strength and hip external rotation isometric strength, which can be done with a manual dynamometer. Moreover, a patient with AKP may have core muscle weakness, so it is also important to evaluate the core muscle endurance.[38] Both core and hip weaknesses lead to dynamic malalignment of the lower extremity that influences patellar tracking. Tibial and femoral rotation should also be evaluated because of their influence on the patellofemoral contact area and pressure[39] (figures 3 and 4). Although lower extremity rotational deformities might increase the risk of AKP, these deformities alone are not enough to provoke AKP; they are only predisposing factors.[40] AKP is correlated with lateralisation of the tibial tubercle (figure 5).[41] When the knee is flexed 90°, the tubercle sulcus angle should be 0°.[42]

Currently, evaluation of the PFJ tends to be done under conditions that simulate realistic functional demands using specific functional tasks rather than specific tests of the patella.[43] Our preferred activity to evaluate patients with AKP is descending the stairs because it is the most demanding of all the activities of

Figure 1 In patients with impingement of the Hoffa fat pad, pain is dramatically exacerbated by quadriceps contraction (B) or passive knee extension (C), while applying pressure of the fat pad with the fingers (A,B,C), because this movement causes a small posterior tilt of the inferior pole of the patella, which impinges on an inflamed and sensitised infrapatellar fat pad.

Figure 2 Assessment of the flexibility of the anterior hip structures.

daily living (ADL) with regard to the knees since it requires substantial control in the quadriceps contraction eccentric phase. Therefore, we perform the step-down task.[17] The patient steps down slowly from a step. In this task, the limb going down only brushes the floor with the heel and then goes back to full knee extension. Moreover, we perform the one-legged squat task (figure 6) and the landing from a drop task.[17] During these tasks, many patients with AKP have an excessive functional knee valgus.[17]

Feet examination is crucial because pronated feet have an important role in the genesis of AKP.[31] Lastly, functional hallux limitus cannot be forgotten as a potential predisposing factor for AKP.[44] It can be demonstrated by a loss of dorsal flexion of the first metatarsophalangeal joint with the ankle in dorsal flexion.[44]

Finally, if an IMPI is suspected, the Fulkerson relocation test is useful.[45] To perform this test, the patella is held medially in extension and then released on abrupt knee flexion. It is a provocative test, and therefore reproduction of symptomatology with this manoeuvre strongly suggests medial patellar instability.

Imaging

AKP is basically a clinical diagnosis, with imaging only assisting to complete the diagnosis. Imaging studies are aimed at quantifying the pathology and checking for other pathologies that could simulate femoropatellar pathology.

The standing anteroposterior view, a true lateral view, and axial X-rays should be obtained for all patients with AKP. These X-rays are the first steps for imaging. In cases refractory to conservative treatment, CT and MRI should be considered. CT shows the bone morphology and allows the measurement of important knee parameters, such as the tibial tubercle-trochlear

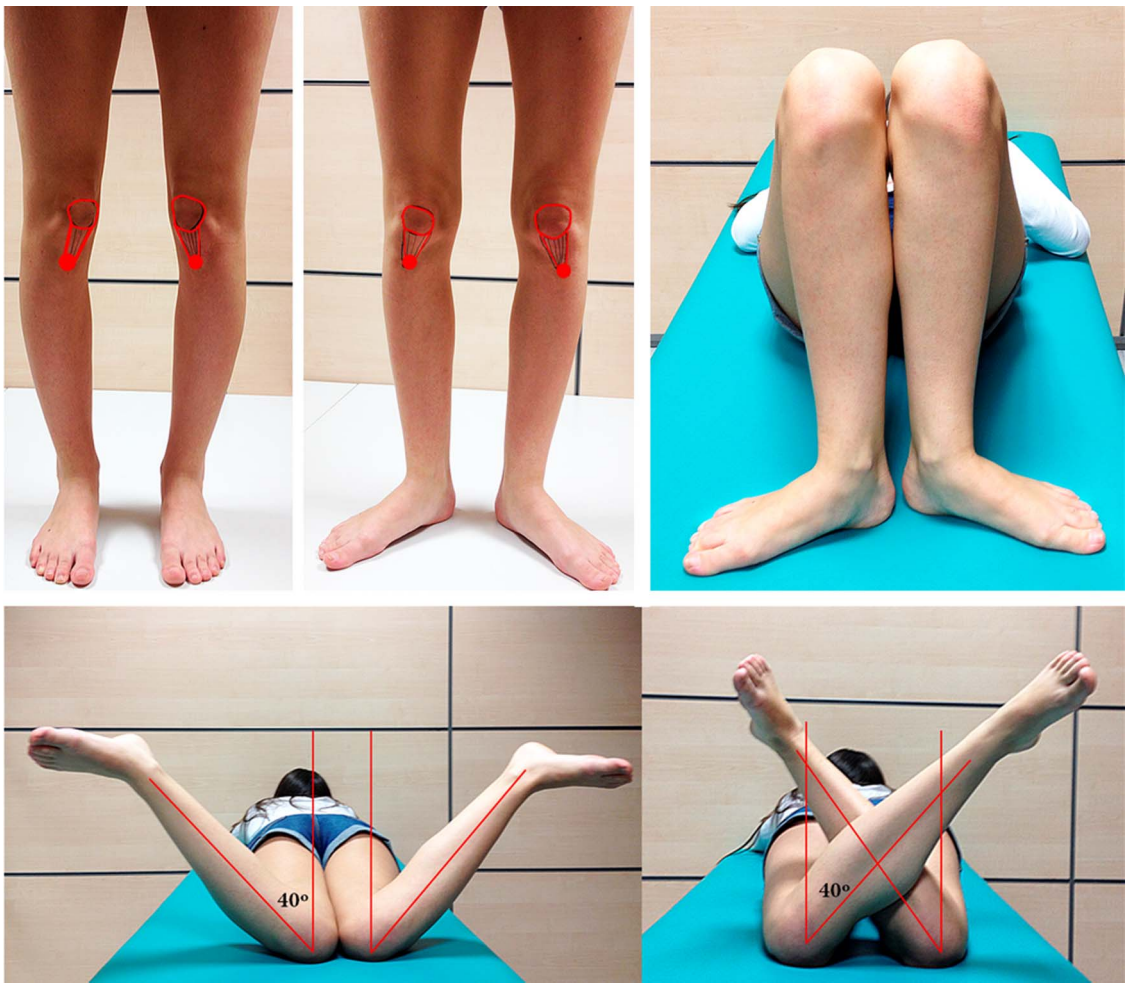

Figure 3 Both internal femoral rotation and external tibial rotation increase pressure on the lateral side of the patellofemoral joint.[39] Squinting patella when the patient is standing with their feet forward. It is due mainly to femoral anteversion, but it can be seen in cases with external tibial torsion without femoral anteversion as occurs in this particular case. Examination of the hips demonstrates equal internal and external rotation. In patients with an increment of the femoral anteversion, the internal rotation of the hip is greater than the external rotation. We must note that increased foot pronation can also lead to increased internal tibial rotation and thus 'squinting patellae'.

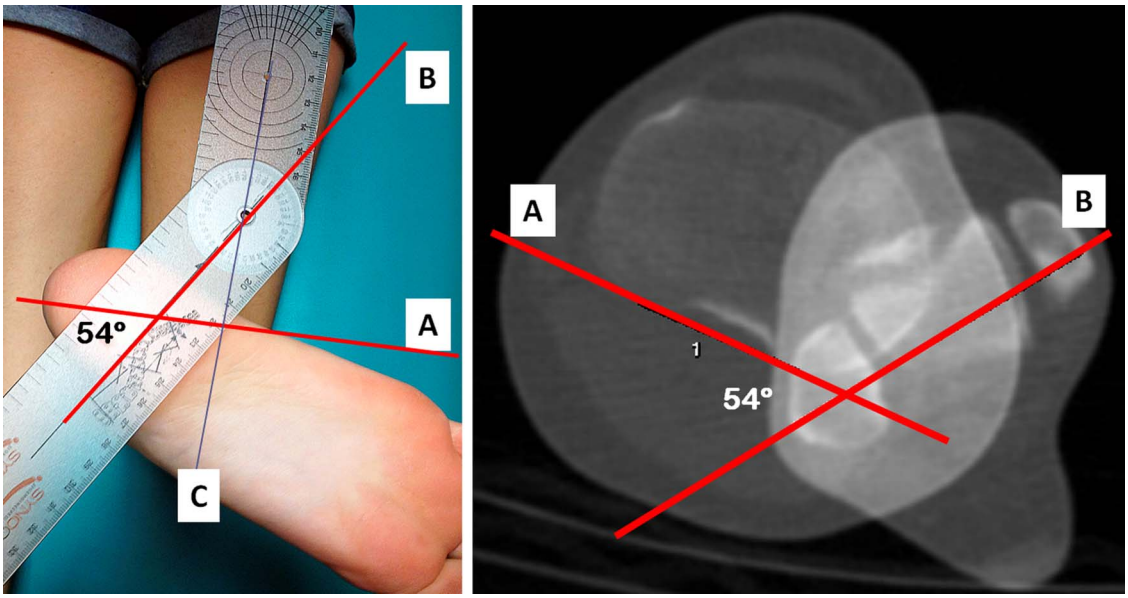

Figure 4 Measurement of external tibial rotation using a goniometer and by means of CT. The patient is positioned prone with the knee flexed to 90° and the ankle in a neutral position of flexion–extension. (A) Transcondylar axis, (C) longitudinal axis of the femur, and (B) transmalleolar axis. The amount of tibial rotation equals the angle AB.

groove distance (TT-TG), that allow for evaluation of maltracking. Moreover, CT scans can detect and quantify torsional anomalies of the lower limbs (figure 4). MRI is useful for detection of cartilage lesions in the PFJ, intraosseous oedema, synovial plica and soft tissue impingement (figure 7). Imaging findings such as lateral patellar displacement may be frequently seen in asymptomatic patients.[31] Patellofemoral chondropathy is also extremely common, and only a small number of patients with a patellar chondral lesion have AKP related to it. Therefore, a surgical option ought never to be based only on imaging techniques, as the correlation between clinical findings and imaging is not good. Three-dimensional CT could be clinically useful in planning revision surgery in patients with AKP after medial patellofemoral ligament reconstruction to detect femoral tunnel malposition (figure 8).[46]

Figure 5 Lateralisation of the tibial tubercle correlates with anterior knee pain. When the knee flexes 90°, the patella usually is captured within the trochlea. In an asymptomatic healthy person, the tibial tubercle femoral sulcus angle should be 0° at 90° of knee flexion. This angle's measurement indicates the lateral displacement of the tubercle with reference to the femoral sulcus.

In selected cases, such as revision surgery or workers' compensation patients, technetium-99m-methylene diphosphonate scintigraphy may be helpful. It shows the metabolic and geographic characteristics of bone homeostasis.[18] A relationship has been demonstrated between an abnormally increased technetium bone scan of the PFJ and AKP.[18] Additionally, an association between restoration to normality of the bone scan and the resolution of AKP after conservative treatment has also been documented.[18] Näslund *et al*[47] found that nearly 50% of patients with AKP show a diffuse uptake in the scintigraphy in one or more of the bony compartments of the knee joint.

Finally, in those cases in which an IMPI is suspected, stress radiography[48] or stress axial CT scans[49] will be helpful. They allow one to objectively document and quantify medial patellar instability. The difference between the displacement of both sides carries more importance than the absolute amount of displacement (figure 9).

NON-OPERATIVE TREATMENT

Since AKP is a multifactorial problem, non-operative management depends on the examination findings. The clinician needs to decrease the strain of excessively loaded and painful soft tissues around the PFJ, improving the seating of the patella in the trochlea, as well as to optimise the lower limb mechanics, which should decrease the patient's symptoms and, if maintained, will minimise any recurrences of symptoms. A multimodal physiotherapy programme is effective in reducing AKP symptoms.[50 51]

Figure 6 Functional or dynamic knee valgus visualised by a one-legged squat. It may lead to lateral patellar maltracking. We can see an internal rotation of the femur secondary to weakness of hip abductors and external rotator muscles. The fact that the patient cannot keep up the hip indicates the weakness of hip abductors. We can observe an internal rotation of the tibia secondary to pes pronatus.

Knee pain inhibits quadriceps contraction, decreasing the loading ability of the knee, whereas fear of pain only decreases vastus medialis oblique (VMO) activity.[52] In middle-aged individuals with decreased quadriceps strength, there are reports of increased knee pain,[53] but MRI scans have also demonstrated increased patellofemoral cartilage loss and tibiofemoral joint space narrowing.[54] Wang *et al*[55] found that optimising the vastus medialis (VM) size was critical to reducing osteoarthritic progression and decreasing the need for a total knee replacement. Recent evidence of the long-term outcome of treatment for adolescents with AKP, who are supposedly compliant with a multimodal exercise programme, is fairly poor, although the same authors found that the majority of adolescents did not perform the home exercises correctly 2 weeks after their initial instruction.[56] It is hypothesised that the adolescents whose symptoms fail to improve will develop PFOA.[57] Therefore, it is imperative for clinicians to ensure from the beginning that they get 'buy in' with the treatment to ensure compliance, so the clinician must educate the patient about why they have symptoms, explaining where the pain is coming from, what has contributed to the pain and in the first visit significantly reduce the symptoms.

Explanation to the patient

A useful tool for clinicians to give a patient is a modified version of Dye's homeostasis of the knee graph, so the patient understands the issues of load intensity and load frequency contributing to AKP symptoms (figure 10). The clinician needs to inform the patient about the effect of ADL on knee joint loading, so the patient understands about keeping inside their envelope of function to ensure that they are not aggravating their symptoms further (box 3).

After the patient has been educated about the effect of load through the knee, the clinician needs to show the patient in front of a mirror his/her lower limb alignment, so the impact of the internally rotated femurs and/or pronated feet can be readily seen. A valuable and easy demonstration to reinforce how proximal and distal factors affect the knee is for the clinician to ask the patient to squeeze their gluteals together, causing external rotation of the femurs and hence a straightening of the knees. The final piece of vital information to improve treatment compliance is for the patient to palpate their size of the fat pad on the symptomatic and asymptomatic sides (the fat pad will be larger in size on the symptomatic side), as well as to feel the direction their patella moves with a quadriceps contraction (the patella will usually move laterally out of the line of the femur). Appropriate education and understanding helps allay the fear of pain, which lessens the likelihood of the condition progressing to complex regional pain syndrome (CRPS).

Recognition and treatment of CRPS

Patients with AKP, manifesting as CRPS, will demonstrate a temperature difference around the knee, with the knee being colder

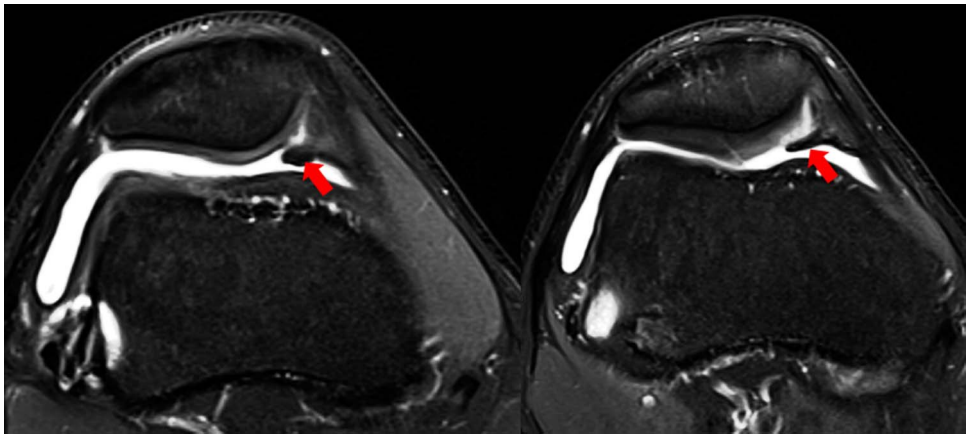

Figure 7 Axial MRI. Impingement of a peripatellar synovitis (arrow).

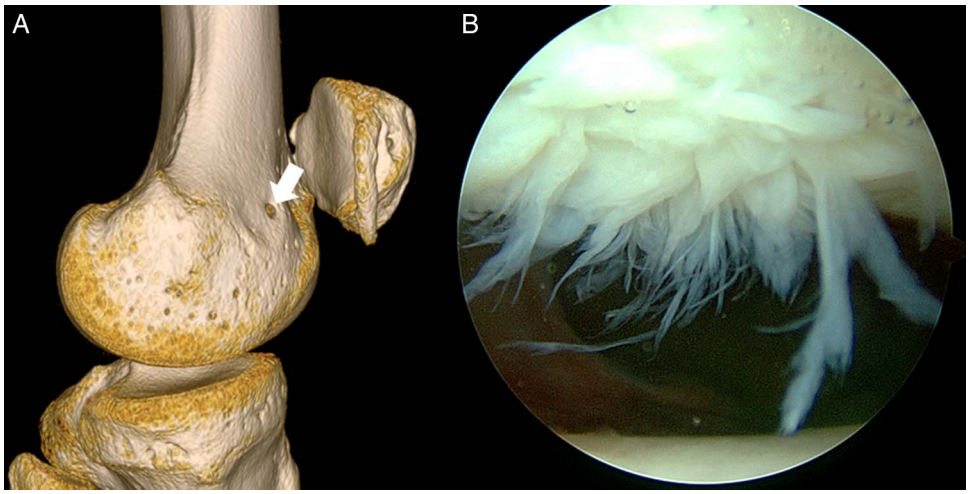

Figure 8 (A) Three-dimensional CT. Observe a very anterior femoral tunnel used for medial patellofemoral ligament reconstruction (arrow) and (B) a severe patellar chondropathy secondary to this surgical mistake.

than the surrounding tissues, particularly the medial aspect. There may also be a mottling of the skin. It is imperative that patients see and feel this so they can understand the effects of the sympathetic nervous system. An explanation of the effects of centrally maintained pain and a regime of desensitising is helpful in breaking the pain cycle (figure 11). While there is a significant temperature difference around the knee, the clinician should not touch the patient's knee or direct specific treatment to the knee as it will make the symptoms worse.

Unloading painful tissues around the knee

This involves improving the position of the patella on the femur with tape and decreasing the stress through any abnormally loaded structure, which in many cases will be the infrapatellar fat pad (IFP).[58 59] Before applying tape, the clinician needs to assess which or all of the following patellar malalignment components are present to determine how best to improve the seating of the patella in the trochlea for each individual patient: (1) posterior tilt of the inferior pole of the patella into the IFP, which is the most critical component to recognise as taping too low on the patella can inflame the IFP; (2) lateral tilt of the patella, indicating tight deep lateral retinacular tissues, which may also need to be stretched manually as well as with tape; (3) lateral glide, indicating tight superficial retinacular structures as well as late onset of VMO contraction and (4) rotation of the inferior pole of the patella such that the long axis of the patella does not align with the long axis of the femur.

A symptom producing weight-bearing activity should be used to determine the effectiveness of the taping, with symptom reduction needing to be at least 50%. In some cases, the fat pad may need to be further unloaded with tape by using two pieces of tape by lifting the fat pad tissue from the tibial tuberosity towards the patella and anchoring behind the medial and lateral epicondyles, respectively (figure 12). The patient needs to keep the tape on all the time until the symptoms have subsided, which means they need to be shown how to tape their own knee, by sitting with the leg out straight on the edge of a chair, so the hamstrings and quadriceps are relaxed and the patella can be easily moved (figure 13).

Additional control of the patellofemoral alignment may be obtained by rotating the femur externally with tape beginning on the femur and anchoring on the sacrum.

Muscle training

In the past, AKP rehabilitation has centred around non-weight-bearing quadriceps activities (straight leg raises and short arc quadriceps—lifting the lower leg over a rolled towel), which have been shown to be not as effective as glutaeal based training in the short term, promoting rectus femoris rather than vasti activity and in some situations shown to aggravate the patient's symptoms, particularly if the IFP is inflamed.[60] For muscle training to have a lasting effect, it should involve changing the way a patient moves, so PFJ loading can change. The exercise programme should therefore consist of neuromuscular, weight-bearing training for the whole lower limb, as the femoral and foot positions contribute to altering patellofemoral loading and weight-bearing promotes balanced quadriceps activation.[61] Jensen *et al*[62] showed that 4 weeks of visuomotor skill training, not strength training, improved corticospinal excitability, reinforcing the importance of training specificity, particularly with regard to gravitational position and force precision.

Figure 9 Axial stress radiograph of the left knee enables us to detect an iatrogenic medial patellar instability.

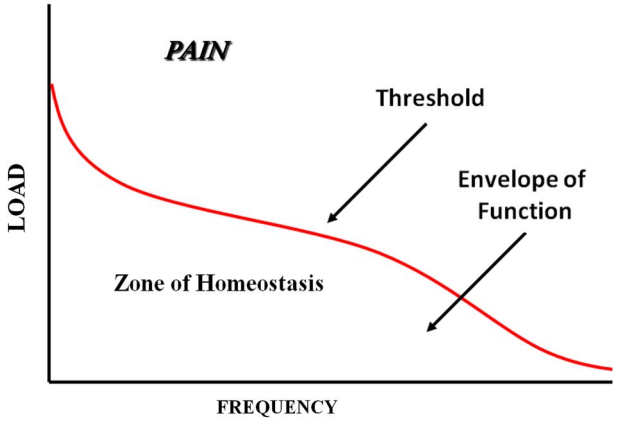

Figure 10 Dye's homeostasis of the knee. To maintain the envelope of function and remain symptom free the patient must keep the intensity and frequency of the load below the threshold.

Since AKP symptoms are generally increased with loaded knee flexion, clinicians need to retrain the limb position initially for walking. To simulate walking, the patient stands next to the wall with their body turned 45° into the wall, with all their weight through the leg furthest from the wall and the knee of the leg closest to the wall bent onto the wall for balance. The patient is instructed to stand tall with the weight back through the heel, posteriorly tilt the pelvis and unlock the knee of the standing leg, while externally rotating the thigh slightly, holding the position for 30 s (figure 14A). Degrees of complexity can be added by using a resistance band tied around the ankle of the non-weight-bearing leg so the patient can pull the band forward and back, increasing the resistance for the walking simulation, as well as changing the surface stability using a bosu ball or, if the patient wants to practise at home, standing on a pillow (figure 14B).

Daily activity training exercises need to be easily incorporated into a patient's life, so while waiting for the elevator or a bus, the patient can squeeze their glutaeals and slightly bend and then straighten, not locking, both knees (the first 30°), keeping their knees over the middle of their feet. Patients can also practise the walk stance position and flex and extend their knees slightly, keeping the knees over the second and third toes. Other daily strategies involve teaching a patient how to sit and stand without using their hands to get up and keeping their hips, knees and feet in alignment (avoiding valgus collapse). Since many individuals are unaware of their posture when they move, mirrors can be incorporated as useful feedback tools early in the rehabilitation programme so that when new activities are added, such as stepping on and off steps and running retraining on a treadmill, the patient can change their position accordingly, based on evaluating their limb position as seen in the mirror. Simple cues are also effective in changing loading such as landing with soft knees or landing further towards the toes as this has been shown to decrease PFJ stress.[63] Decreased tibiofemoral dorsiflexion and subtalar mobility increases the dynamic valgus collapse seen in many individuals with AKP, so the

Box 3 The patellofemoral joint (PFJ) reaction force and activities of daily living

- 0.5× body weight through PFJ with level walking.
- 1.5× body weight through PFJ with cycling on a stationary bike.
- 3–4× body weight through PFJ with ascending and descending stairs.
- 7–8× body weight through PFJ with squatting.
- 20× body weight through PFJ with jumping.

Figure 11 Desensitising the knee—a variety of different textured objects need to be rubbed around the knee by the patient. The objects could include tissue, cotton wool, sandpaper, ice, etc. This needs to be done for 5 min every day—30 s to 1 min with each object for about a month.

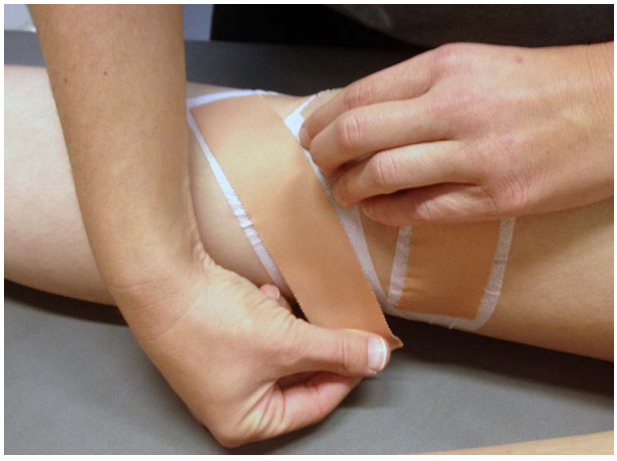

Figure 12 Unloading the fat pad—the tape needs to start on the superior half of the patella to tilt the inferior pole of the patella out of the fat pad, then the fat pad needs to be unloaded by starting at the tibial tubercle with each piece of tape and taping towards the medial and lateral joint lines, forming a wide v shape. The soft tissue is lifted towards the patella to decrease the tension on the tissues.

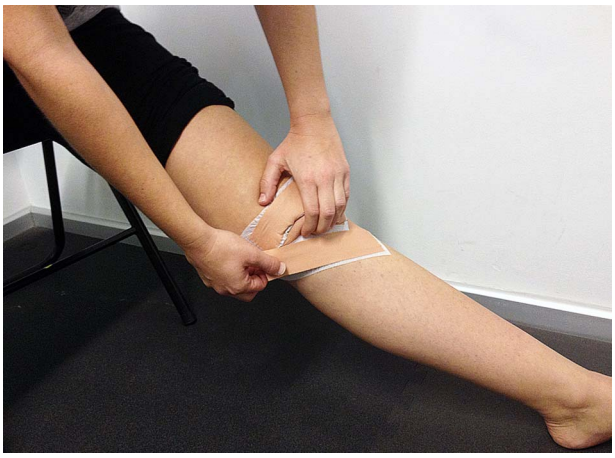

Figure 13 Self-tape—the patient sits on the edge of a chair with the leg relaxed and extended so it is easy to move the patella. This is a particularly good way to achieve patella correction as it eliminates the problem of tight hamstrings causing knee flexion which can be a problem when the patient tapes the knee in long sitting.

clinician can mobilise to increase the range of the joint/s responsible (figure 15).[64]

The clinician needs to give advice about footwear and orthotics. If the navicular drop test is positive (ie, if there is a large difference between the non-weight-bearing and weight-bearing arch height), then off the shelf foot orthotics are helpful in minimising patellofemoral symptoms.[65] Although some authors have found that some patients with AKP are that running barefoot is better for patients with AKP as it decreases PFJ stress, so they recommend minimalist running shoes with no orthotics, so there is scope for further investigation identifying different foot postures, categorising responders and non-responders to foot or no foot intervention.

Figure 14 (A) Glutaeal training—the patient stands 45° towards the wall, lifts the knee of the leg closest to the wall onto the wall for balance. All the patient's weight is on the standing leg, the weight is back through the heel, the standing knee is slightly flexed, the pelvis is slightly posteriorly tilted. The patient stands tall and very slightly rotates the standing leg thigh, so the patient feels the glutaeals burning. This exercise is performed frequently throughout the day. This is brain training—changing the synergistic activation pattern of the lower extremity muscles for walking and running. (B) This exercise can be progressed by having the patient stand on a pillow to simulate rough ground.

Figure 15 Mobilisation of the subtalar joint—this is performed in side-lying with the foot maintained at neutral dorsiflexion to simulate heel strike. The clinician everts the calcaneum to increase subtalar pronation immediately after heel strike.

Since muscle tightness can contribute to AKP symptoms, appropriate stretches should be included in the treatment regimen. The involved muscles may include anterior hip structures, hamstrings, gastrocnemius, rectus femoris as well as tensor fasciae latae (TFL)/ITB (figure 16).

Body management strategies

Lankhorst *et al*[66] recently found that patients with AKP who have a delay in initiating treatment and a lower AKP scale at

Figure 16 Hamstrings stretch—the patient sits on a kitchen bench or somewhere so the legs do not touch the ground. The patient sits tall—maintaining a neutral spine, and trunk at 90° to the hips, then the patient straightens the leg without losing control of the trunk position. This position is held for 15 s and repeated. The leg should not fully extend, as this will irritate the fat pad—if the clinician is worried about the fat pad being inflamed, then the patient can lean further forward while maintaining a neutral spine which will decrease the load through the patellofemoral joint.

diagnosis are more likely to still have knee pain 6–8 years later, concluding that clinicians need to send patients for appropriate treatment early. For improved long-term outcome for patients with AKP, there should be a paradigm shift in the way clinicians manage AKP. Since the word exercise conjures up an onerous, time-consuming message to many patients, clinicians need to empower individuals to take charge of their symptoms, emphasising the need to reinforce appropriate limb alignment with daily practice, requiring a small amount of time, just like they would keep their teeth in good health by regular brushing. To ensure the success of the daily strategies and to keep symptoms under control, the patient would need to visit the clinician every 6 months or 12 months for a 'body maintenance check', similar to a car service, but for the body, as chronic musculoskeletal conditions are not cured but are managed, so this is one way that could ensure long-term compliance with a self-management programme.

SURGICAL TREATMENT

The primary treatment for all patients with AKP is non-operative. When non-operative measures fail, and when a patient is in a dysfunctional state requiring intervention, the goal must be to identify the specific mechanical and/or physical origin of the pain before considering any surgery. One should also understand if catastrophising and kinesiophobia are significant factors before contemplating surgery because psychological factors are pain modulators.[20] However, their presence does not contraindicate surgery if there are objective abnormalities and if exhaust non-operative measures have failed. The first goal is to identify whether the pain is articular or extra-articular. The following entities may be treated successfully with surgery.

Plica/localised synovial hypertrophy

A pathological, painful plica is most readily identified by palpating it in the region in which the patient notes pain, usually in the medial infrapatellar space. Painful plica may be found in other parts of the knee joint too, so careful palpation around the joint will identify if there is snapping or evidence of a tender intra-articular band of tissue which might be causing pain. In such cases, the best treatment is arthroscopic resection of the painful intra-articular impinging synovial plica structure. Localised synovial hypertrophy around the inferior pole of the patella and impingement of a peripatellar synovitis (figure 17) could also be successfully treated by means of electrosurgical synovectomy.[18 67]

Retinacular pain

As identified by Kasim and Fulkerson,[68] any peripatellar retinacular structure could be a source of AKP. Such pain often goes undiagnosed and is most readily identified by careful palpation of every component around the patella, above and below as well as medial and lateral to the patella itself, looking for a source of tenderness which reproduces the patient's pain. Such causes of pain may be treated effectively by injection of a corticosteroid and/or stretching, but when chronic, retinacular pain is disabling, local excision or release may be beneficial and curative. Therefore, identification and surgical extirpation of a chronic source of retinacular pain are important. Such retinacular pain sources may be related to chronic stress as in a chronically tilted patella causing pain in the lateral retinaculum. The vastus lateralis tendon may become constantly irritated in some patients. Pain in the VM tendon, the patellar tendon or the quadriceps tendon are treatable by surgical eradication of the chronically irritated tissue. Such retinacular pain is sometimes associated

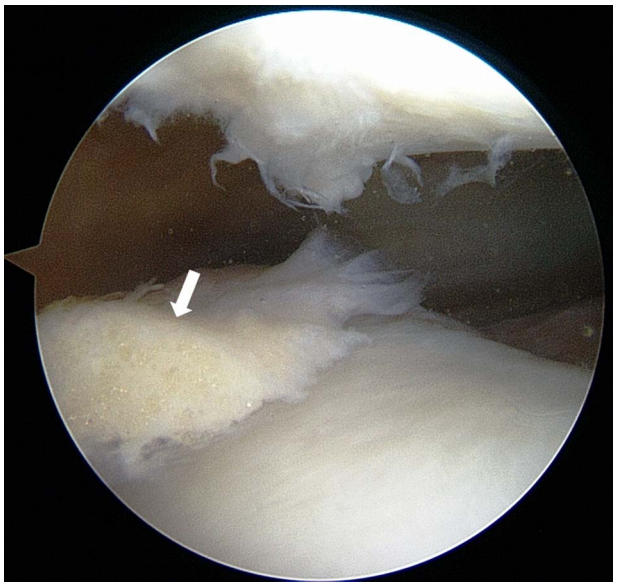

Figure 17 Peripatellar synovitis (arrow).

with small nerve injury[13 16] and/or substance P production.[69] Eradication or transection of the painful small nerves causing this pain through a localised excision or release is usually successful.[68] One must be particularly careful, however, not to create a patella imbalance by release of a painful retinacular structure that might be also giving important support within the extensor mechanism. This will be particularly true in patients with trochlear dysplasia and imbalance around the patella. In such patients, appropriate treatment of the imbalance and/or compensatory surgery for the dysplasia may be necessary at the time of retinacular resection or release. Electrosurgical arthroscopic patellar denervation could be a good solution for selected patients with recalcitrant patellofemoral pain without evident mechanical anomalies.[70]

Articular pain

Articular causes of AKP have been poorly understood. The connection between articular lesions of the patella or trochlea and AKP is variable. Many patients with patellofemoral articular lesions have no pain, whereas some people, with cartilage softening only, have excruciating, disabling pain. Therefore, it behoves the surgeon who is contemplating intervention to assure whether or not a patellofemoral articular lesion is a source of pain. Clinical examination and imaging are essential, along with a detailed history regarding pain triggers. Between the history, observation of the patient doing a single-leg knee bend, and imaging studies to find potential areas of focal overload, painful lesion localisation should be possible in the majority of cases. Fluid signal change on T2-weighted MRIs are diagnostic, as is a positive radionuclide scan. Ho *et al*[71] have shown fluid signal changes in subchondral bone correlated with overload. If the imaging studies match the degree of knee flexion in which pain occurs, one has most likely found an articular pain source.

Unfortunately, imaging studies do not necessarily identify a lesion in all cases. The presence of an objective tilt on axial radiography strongly supports focal overload of the lateral PFJ, but a lack of tilt does not rule out focal overload of the distal or lateral patella that may occur functionally in some patients, most often female, with delayed centring of the patella in the femoral

Box 4 Key issues in patient selection for surgical procedures in the treatment of patellofemoral pain

- Exhaust all non-operative treatment methods first.
- Be aware of catastrophising and kinesiophobia and be particularly sure of objective findings in patients prone to this condition.
- In patients who have already had a patellofemoral surgery, be particularly suspicious of complex instability problems such as medial subluxation and neuroma.
- Most patients have real pain and one should not assume that non-operative measures will work in all patients.
- Make sure that the patient understands the nature of any proposed surgery and also be sure that the patient cannot live with the pain. Modification of activity may be an acceptable alternative to some, particularly older patients.
- Design the surgical approach very specifically to target sites of pain generation.
- Be sure to have permission for any potential procedure that might be needed at the time of surgery.
- Complex regional pain problems should be treated before surgical intervention, and surgical intervention should be carefully coordinated with any pain management that is ongoing.

Box 5 Tips and tricks in the surgical treatment of patellofemoral pain

- Use exhaustive physical examination and imaging, and sometimes diagnostic arthroscopy, to accurately define the site of pain origin.
- Use minimalistic approaches whenever possible and appropriate.
- Use arthroscopy as a diagnostic tool as well as for treatment. Treatment options may vary depending on specific arthroscopic findings. Don't perform lateral release for medial softening. Lateral release is indicated only for lateral softening with patella tilt and a tight lateral retinaculum.
- Drilling of articular lesions on the patella should generally be accompanied by rest and motion with limited weight-bearing and loading of the joint for about 6 weeks in most patients.
- Unloading of a painful articular lesion on the distal and/or lateral patella by anteromedial tibial tubercle transfer, when the patella is overloaded laterally, is a powerful surgical option in the treatment of patellofemoral pain resulting from lateral patella cartilage softening or breakdown.
- Lateral retinacular release or lengthening will often give relief of pain in patients with isolated patella tilt with minimal cartilage breakdown and a tight retinaculum.
- Release only what is needed and never release without a good objective reason to do so.
- Always encourage early motion without weight-bearing only after tibial tuberosity osteotomy or drilling—one bend a day is all that is needed.
- Maintain quadriceps tone after surgery.

trochlea in early knee flexion. Such patients may have dysfunction originating at the hip or knee level, or structural trochlea dysplasia may lead to focal overload of the distal and/or distal/lateral patella that is held on the lateral trochlea too long in early knee flexion. Pain in such patients typically occurs on stepping down with the contralateral leg. Thus, the distal patella of the affected side is brought into the focal overload orientation on entry into the trochlea with initial knee flexion. Such problems may be ameliorated by core strengthening, VMO strengthening and non-operative work including mobilisation that benefits patellofemoral tracking, but such treatment often fails once articular cartilage has begun to deteriorate causing chronic focal subchondral bone irritation. This is first manifested as softening or blistering of the overloaded distal/lateral or lateral patella articular cartilage from recurrent focal overload related to structural malalignment and/or functional imbalance (s) of the extensor mechanism.

Some patients may experience painful clicking related to a loose articular fragment in which case an arthroscopic chondroplasty may provide considerable relief. Microfracture or abrasion arthroplasty has typically been less effective on the patella.

Lateral facetectomy has been helpful in some patients with specific impingement on the lateral overhanging facet. Unloading of a painful lateral patella articular lesion by anteromedialization (AMZ) of the tibial tuberosity,[12] however, provides more profound and prolonged benefit than lateral facetectomy.

Treatment is best directed at relief of pressure on the area of patella focal overload. In patients with an objective patella tilt and a tight lateral retinaculum, lateral release or lengthening may be highly effective to unload the lateral, overloaded patella facet. When the distal patella is more severely involved and changes extend towards the distal, medial or central aspect of the patella, lateral release alone may not be sufficient. Subchondral drilling followed by 6 weeks' immobilisation works in some patients, presumably by creating a subchondral 'healing response' and opportunity for restoration of subchondral homeostasis.[18] In this particular case, we recommend immobilisation because we are looking for subchondral reconstitution, not cartilage restitution. Bone marrow stimulation by drilling adds the possibility of deep cartilage restoration and subchondral remodelling. In patients with AKP and patellar hypertension, extra-articular patellar decompression may offer good results.[72]

AMZ provides more profound unloading of the distal and lateral patella when focal overload related to patella malalignment cannot be relieved sufficiently by lateral lengthening or release. Once the lateral articular cartilage has collapsed, lateral release is less effective and definitive unloading by AMZ may be necessary.[73] Pain relief and return to sports are expected after AMZ for appropriate patients.[74] In selected cases, torsional correction surgery should be considered.[75]

In more extreme cases in which patellofemoral articular pain is related to focal or diffuse patellofemoral injury which cannot be relieved by unloading, articular resurfacing may be warranted. A painful medial or trochlear articular lesion may be excised and resurfaced by an autogenous osteoarticular transplant, allograft or biological resurfacing procedure, but results with these approaches have been mixed. Osteoarticular allograft resurfacing may be appropriate and can be highly effective in relieving pain, but carry the risk of late failure.[76] Similarly, patellofemoral arthroplasty may become necessary, particularly in older patients and patients with more diffuse patellofemoral destruction. In general, most patients with patellofemoral

Box 6 Pitfalls of patellofemoral surgery for pain

- Lateral release of a patella that does not have tilt and a tight lateral retinaculum may cause medial instability or subluxation thereby making the patient worse.
- Ignoring or missing a symptomatic patella articular lesion will often yield an unsuccessful surgery, particularly if load is added to the lesion inadvertently.
- A tibial tubercle transfer osteotomy that is not flat, tapered anteriorly at the distal osteotomy, or poorly stabilised will put the patient at risk.
- Retinacular causes of pain are often missed and must be identified and treated to gain optimal pain relief. Sometimes this requires a local excision of neuromatous or chronically irritated tissue.

articular sources of pain, however, can be managed with releasing and unloading alternatives.

FUTURE DIRECTIONS

The most challenging patient with AKP in terms of treatment is the neuropathic patient. Current data suggest that repetitive transcranial magnetic stimulation of the motor cortex, corresponding to the patients' site of pain, could be a complementary treatment for patients with chronic neuropathic pain.[77 78] This treatment could therefore be considered in the subset of patients with neuropathic pain not responding to more conventional treatments. Another emerging promising method in the management of AKP in patients for whom conservative or surgical therapy has failed is radiofrequency neurotomy.[79]

Finally, we are convinced that the so-called biopsychosocial model, currently used in chronic lumbar pain, will soon be applied in patients with AKP to better understand what is happening in them.[80] According to this model, anatomic, biological and biomechanical factors must be considered to understand pain, as well as psychological and social factors. Among all the psychological factors that have been analysed in the patient with AKP, the most relevant one from a clinical standpoint is catastrophising, which is related to pain as well as to disability.[20] Consequently, cognitive behavioural interventions which have shown the reduction of catastrophising pain in patients with arthritis or lumbar pain could also be helpful in patients suffering from AKP.[81 82] In this way, we must note that psychological intervention in patients who underwent anterior cruciate ligament reconstruction has shown significant improvements in the short-term clinical results and functional outcomes.[83] Catastrophising represents a barrier in the recovery from pain and disability, and therefore it should be included in the therapeutic targets to complement and to improve the results of conventional treatments (such as physical therapy and/or surgery) (boxes 4–6).

Competing interests None declared.

Provenance and peer review Commissioned; externally peer reviewed.

REFERENCES

1 Barber Foss KD, Hornsby M, Edwards NM, *et al*. Is body composition associated with an increased risk of developing anterior knee pain in adolescent female athletes? *Phys Sportsmed* 2012;40:13–19.
2 Nejati P, Forogh B, Moeineddin R, *et al*. Patellofemoral pain syndrome in Iranian female athletes. *Acta Med Iran* 2011;49:169–72.
3 Boling M, Padua D, Marshall S, *et al*. Gender differences in the incidence and prevalence of patellofemoral pain syndrome. *Scand J Med Sci Sports* 2010;20:723–30.
4 Collins NJ, Bierma-Zeinstra SM, Crossley KM, *et al*. Prognostic factors for patellofemoral pain: a multicentre observational analysis. *Br J Sports Med* 2013;47:227–33.
5 Powers CM, Bolgla LA, Callaghan MJ, *et al*. Patellofemoral pain: proximal, distal, and local factors, 2nd International Research Retreat. *J Orthop Sports Phys Ther* 2012;42:A1–54.
6 Boccard SG, Fitzgerald JJ, Pereira EA, *et al*. Targeting the affective component of chronic pain: a case series of deep brain stimulation of the anterior cingulate cortex. *Neurosurgery* 2014;74:628–35.
7 Domenech J, Sanchis-Alfonso V, López L, *et al*. Influence of kinesiophobia and catastrophizing on pain and disability in anterior knee pain patients. *Knee Surg Sports Traumatol Arthrosc* 2013;21:1562–8.
8 Tan SS, van Linschoten RL, van Middelkoop M, *et al*. Cost-utility of exercise therapy in adolescents and young adults suffering from the patellofemoral pain syndrome. *Scand J Med Sci Sports* 2010;20:568–79.
9 Crossley KM. Is patellofemoral osteoarthritis a common sequela of patellofemoral pain? *Br J Sports Med* 2014;48:409–10.
10 Rankin G, Rushton A, Olver P, *et al*. Chartered Society of Physiotherapy's identification of national research priorities for physiotherapy using a modified Delphi technique. *Physiotherapy* 2012;98:260–72.
11 Merchant AC, Mercer RL, Jacobsen RH, *et al*. Roentgenographic analysis of patellofemoral congruence. *J Bone Joint Surg Am* 1974;56:1391–6.
12 Fulkerson JP. Anteromedialization of the tibial tuberosity for patellofemoral malalignment. *Clin Orthop Relat Res* 1983;(177):176–81.
13 Fulkerson JP, Tennant R, Jaivin JS, *et al*. Histologic evidence of retinacular nerve injury associated with patellofemoral malalignment. *Clin Orthop Relat Res* 1985;197:196–205.
14 Hughston JC, Deese M. Medial subluxation of the patella as a complication of lateral retinacular release. *Am J Sports Med* 1988;16:383–8.
15 McConnell J. Management of patellofemoral problems. *Man Ther* 1996;1:60–6.
16 Sanchis-Alfonso V, Roselló-Sastre E, Monteagudo-Castro C, *et al*. Quantitative analysis of nerve changes in the lateral retinaculum in patients with isolated symptomatic patellofemoral malalignment. A preliminary study. *Am J Sports Med* 1998;26:703–9.
17 Powers CM. The influence of altered lower-extremity kinematics on patellofemoral joint dysfunction: a theoretical perspective. *J Orthop Sports Phys Ther* 2003;33:639–46.
18 Dye SF. The pathophysiology of patellofemoral pain: a tissue homeostasis perspective. *Clin Orthop Relat Res* 2005;436:100–10.
19 Näslund J, Waldén M, Lindberg LG. Decreased pulsatile blood flow in the patella in patellofemoral pain syndrome. *Am J Sports Med* 2007;35:1668–73.
20 Doménech J, Sanchis-Alfonso V, Espejo B. Changes in catastrophizing and kinesiophobia are predictive of changes in disability and pain after treatment in patients with anterior knee pain. *Knee Surg Sports Traumatol Arthrosc* 2014;22:2295–300.
21 Abernethy PJ, Townsend PR, Rose RM, *et al*. Is chondromalacia patellae a separate clinical entity? *J Bone Joint Surg Br* 1978;60-B:205–10.
22 Rathleff MS, Roos EM, Olesen JL, *et al*. Lower mechanical pressure pain thresholds in female adolescents with patellofemoral pain syndrome. *J Orthop Sports Phys Ther* 2013;43:414–21.
23 Sanchis-Alfonso V, Merchant AC. Iatrogenic medial patellar instability: an avoidable injury. *Arthroscopy* 2015;31:1628–32.
24 Crossley KM, Bennell KL, Cowan SM, *et al*. Analysis of outcome measures for persons with patellofemoral pain: which are reliable and valid? *Arch Phys Med Rehabil* 2004;85:815–22.
25 Bennett MI, Smith BH, Torrance N, *et al*. The S-LANSS score for identifying pain of predominantly neuropathic origin: validation for use in clinical and postal research. *J Pain* 2005;6:149–58.
26 Kujala UM, Jaakkola LH, Koskinen SK, *et al*. Scoring of patellofemoral disorders. *Arthroscopy* 1993;9:159–63.
27 Tegner Y, Lysholm J. Rating systems in the evaluation of knee ligament injuries. *Clin Orthop Relat Res* 1985;(198):43–9.
28 Zigmond AS, Snaith RP. The Hospital Anxiety and Depression Scale. *Acta Psychiatr Scand* 1983;67:361–70.
29 Sullivan MJL, Bishop SR, Pivik J. The Pain Catastrophizing Scale: development and validation. *Psychol Assess* 1995;7:524–32.
30 Kori KS, Miller RP, Todd DD. Kinesiophobia: a new view of chronic pain behavior. *Pain Mang* 1990;3:35–43.
31 Sanchis-Alfonso V, Montesinos-Berry E, Serrano A, *et al*. Evaluation of the patient with anterior knee pain and patellar instability. In: Sanchis-Alfonso V, ed. *Anterior Knee pain and patellar instability*. London: Springer, 2011:105–22.
32 Hejgaard N, Arnoldi CC. Osteotomy of the patella in the patellofemoral pain syndrome. The significance of increased intraosseous pressure during sustained knee flexion. *Int Orthop* 1984;8:189–94.

33 Dragoo JL, Johnson C, McConnell J. Evaluation and treatment of disorders of the infrapatellar fat pad. *Sports Med* 2012;42:51–67.
34 Pappas E, Wong-Tom WM. Prospective predictors of patellofemoral pain syndrome: a systematic review with meta-analysis. *Sports Health* 2012;4:115–20.
35 Baker V, Bennell K, Stillman B, *et al*. Abnormal knee joint position sense in individuals with patellofemoral pain syndrome. *J Orthop Res* 2002;20:208–14.
36 Sanchis-Alfonso V, Tey M, Monllau JC. A novel association between femoroacetabular impingement and anterior knee pain. *Pain Res Treat* 2015;2015:937431.
37 Prins MR, van der Wurff P. Females with patellofemoral pain syndrome have weak hip muscles: a systematic review. *Aust J Physiother* 2009;55:9–15.
38 Earl JE, Hoch AZ. A proximal strengthening program improves pain, function, and biomechanics in women with patellofemoral pain syndrome. *Am J Sports Med* 2011;39:154–63.
39 Lee TQ, Morris G, Csintalan RP. The influence of tibial and femoral rotation on patellofemoral contact area and pressure. *J Orthop Sports Phys Ther* 2003;33:686–93.
40 Erkocak OF, Altan E, Altintas M, *et al*. Lower extremity rotational deformities and patellofemoral alignment parameters in patients with anterior knee pain. *Knee Surg Sports Traumatol Arthrosc* 2015. Published Online First.
41 Muneta T, Yamamoto H, Ishibashi T, *et al*. Computerized tomographic analysis of tibial tubercle position in the painful female patellofemoral joint. *Am J Sports Med* 1994;22:67–71.
42 Hughston JC, Walsh WM, Puddu G. Patellar subluxation and dislocation. Philadelphia: WB Saunders, 1984.
43 Papadopoulos K, Stasinopoulos D, Ganchev D. A systematic review of reviews in patellofemoral pain syndrome. Exploring the risk factors, diagnostic tests, outcome measurements and exercise treatment. *Open Sports Med J* 2015;9:7–17.
44 Vallotton J, Echeverri S. Clinical examination of the patellofemoral patient. In: Zaffagnini S, Dejour D, Arendt EA, eds. *Patellofemoral pain, instability, and arthritis*. Berlin: Springer, 2010:41–9.
45 Fulkerson JP. A clinical test for medial patella tracking. *Tech Orthop* 1997;12:144.
46 Sanchis-Alfonso V, Ramírez-Fuentes C, Montesinos-Berry E, *et al*. Femoral insertion site of the graft used to replace the medial patellofemoral ligament influences the ligament dynamic changes during knee flexion as well as clinical outcome. *Knee Surg Sports Traumatol Arthrosc* 2015 Dec 12 [Epub ahead of print] doi:10.1007/s00167-015-3905-0
47 Näslund JE, Odenbring S, Näslund UB, *et al*. Diffusely increased bone scintigraphic uptake in patellofemoral pain syndrome. *Br J Sports Med* 2005;39:162–5.
48 Teitge RA, Faerber WW, Des Madryl P. Stress radiographs of the patellofemoral joint. *J Bone Joint Surg Am* 1996;78-A:193–203.
49 Biedert RM. Computed tomography examination. In: Biedert RM, ed. *Patellofemoral disorders. Diagnosis and treatment*. West Sussex: Wiley, 2004:101–11.
50 Crossley K, Bennell K, Green S. Physical therapy for patellofemoral pain: a randomized, double-blinded, placebo-controlled trial. *Am J Sports Med* 2002;30:857–65.
51 Cowan SM, Bennell KL, Crossley KM. Physical therapy alters recruitment of the vasti in patellofemoral pain syndrome. *Med Sci Sports Exerc* 2002;34:1879–85.
52 Hodges PW, Mellor R, Crossley K, *et al*. Pain induced by injection of hypertonic saline into the infrapatellar fat pad and effect on coordination of the quadriceps muscles. *Arthritis Rheum* 2009;61:70–7.
53 Amin S, Baker K, Niu J, *et al*. Quadriceps strength and the risk of cartilage loss and symptom progression in knee osteoarthritis. *Arthritis Rheum* 2009;60:189–98.
54 Segal NA, Glass NA, Torner J, *et al*. Quadriceps weakness predicts risk for knee joint space narrowing in women in the MOST cohort. *Osteoarthr Cartil* 2010;18:769–75.
55 Wang Y, Wluka AE, Berry PA, *et al*. Increase in vastus medialis cross-sectional area is associated with reduced pain, cartilage loss, and joint replacement risk in knee osteoarthritis. *Arthritis Rheum* 2012;64:3917–25.
56 Faber M, Andersen MH, Sevel C, *et al*. The majority are not performing home-exercises correctly two weeks after their initial instruction—an assessor-blinded study. *Peer J* 2015;3:e1102.
57 Rathleff MS, Vicenzino B, Middelkoop M, *et al*. Patellofemoral pain in adolescence and adulthood: same same, but different? *Sports Med* 2015;45:1489–95.
58 Derasari A, Brindle TJ, Alter KE, *et al*. McConnell taping shifts the patella inferiorly in patients with patellofemoral pain: a dynamic magnetic resonance imaging study. *Phys Ther* 2010;90:411–19.
59 Handfield T, Kramer J. Effect of McConnell taping on perceived pain and knee extensor torques during isokinetic exercise performed by patients with patellofemoral pain syndrome. *Physiotherapy Canada* 2000;4:39–44.
60 Escamilla RF, Fleisig GS, Zheng N. Biomechanics of the knee during closed kinetic chain and open kinetic chain exercises. *Med Sci Sports Exerc* 1998;30:556–69.
61 Stensdotter AK, Hodges PW, Mellor R, *et al*. Quadriceps activation in closed and in open kinetic chain exercise. *Med Sci Sports Exerc* 2003;35:2043–7.
62 Jensen JL, Marstrand PC, Nielsen JB. Motor skill training and strength training are associated with different plastic changes in the central nervous system. *J Appl Physiol* 2005;99:1558–68.
63 Bonacci J, Vicenzino B, Spratford W, *et al*. Take your shoes off to reduce patellofemoral joint stress during running. *Br J Sports Med* 2014;48:425–8.
64 Wyndow N, De Jong A, Rial K, *et al*. The relationship of foot and ankle mobility to the frontal plane projection angle in asymptomatic adults. *J Foot Ankle Res* 2016;9:3.
65 McPoil TG, Warren M, Vicenzino B, *et al*. Variations in foot posture and mobility between individuals with patellofemoral pain and those in a control group. *J Am Podiatr Med Assoc* 2011;101:289–96.
66 Lankhorst NE, van Middelkoop M, Crossley KM, *et al*. Factors that predict a poor outcome 5–8 years after the diagnosis of patellofemoral pain: a multicentre observational analysis. *Br J Sports Med* Published Online First: 13 Oct 2015. doi:10.1136/bjsports-2015-094664.
67 Maier D, Bornebusch L, Salzmann GM, *et al*. Mid- and long-term efficacy of the arthroscopic patellar release for treatment of patellar tendinopathy unresponsive to nonoperative management. *Arthroscopy* 2013;29:1338–45.
68 Kasim N, Fulkerson JP. Resection of clinically localized segments of painful retinaculum in the treatment of selected patients with anterior knee pain. *Am J Sports Med* 2000;28:811–14.
69 Sanchis-Alfonso V, Roselló-Sastre E. Immunohistochemical analysis for neural markers of the lateral retinaculum in patients with isolated symptomatic patellofemoral malalignment. A neuroanatomic basis for anterior knee pain in the active young patient. *Am J Sports Med* 2000;28:725–31.
70 Vega J, Golanó P, Pérez-Carro L. Electrosurgical arthroscopic patellar denervation. *Arthroscopy* 2006;22:1028.e1–3.
71 Ho KY, Hu HH, Colletti PM, *et al*. Recreational runners with patellofemoral pain exhibit elevated patella water content. *Magn Reson Imaging* 2014;32:965–8.
72 Miltner O, Siebert CH, Schneider U, *et al*. Patellar hypertension syndrome in adolescence: a three-year follow up. *Arch Orthop Trauma Surg* 2003;123:455–9.
73 Fulkerson JP, Becker GJ, Meaney JA, *et al*. Anteromedial tibial tubercle transfer without bone graft. *Am J Sports Med* 1990;18:490–6.
74 Tjoumakaris FP, Forsythe B, Bradley JP. Patellofemoral instability in athletes: treatment via modified Fulkerson osteotomy and lateral release. *Am J Sports Med* 2010;38:992–9.
75 Stevens PM, Gililland JM, Anderson LA, *et al*. Success of torsional correction surgery after failed surgeries for patellofemoral pain and instability. *Strategies Trauma Limb Reconstr* 2014;9:5–12.
76 Gracitelli GC, Meric G, Pulido PA, *et al*. Fresh osteochondral allograft transplantation for isolated patellar cartilage injury. *Am J Sports Med* 2015;43:879–84.
77 Young NA, Sharma M, Deogaonkar M. Transcranial magnetic stimulation for chronic pain. *Neurosurg Clin N Am* 2014;25:819–32.
78 Treister R, Lang M, Klein MM, *et al*. Non-invasive Transcranial Magnetic Stimulation (TMS) of the motor cortex for neuropathic pain-at the tipping point? *Rambam Maimonides Med J* 2013;29:e0023.
79 Franco CD, Buvanendran A, Petersohn JD, *et al*. Innervation of the anterior capsule of the human knee: implications for radiofrequency ablation. *Reg Anesth Pain Med* 2015;40:363–8.
80 Leeuw M, Goossens ME, Linton SJ, *et al*. The fear-avoidance model of musculoskeletal pain: current state of scientific evidence. *J Behav Med* 2007;30:77–94.
81 Dixon KE, Keefe FJ, Scipio CD, *et al*. Psychological interventions for arthritis pain management in adults: a meta-analysis. *Health Psychol* 2007;26:241–50.
82 Chou R, Baisden J, Carragee EJ, *et al*. Surgery for low back pain: a review of the evidence for an American Pain Society Clinical Practice Guideline. *Spine* 2009;34:1094–109.
83 Zaffagnini S, Russo RL, Marcheggiani Muccioli GM, *et al*. The Videoinsight® method: improving rehabilitation following anterior cruciate ligament reconstruction—a preliminary study. *Knee Surg Sports Traumatol Arthrosc* 2013;21:851–8.

Diagnosis and treatment of anterior knee pain

Vicente Sanchis-Alfonso, Jenny McConnell, Joan Carles Monllau and John P Fulkerson

J ISAKOS published online March 22, 2016